



Histopathological Evaluation of Liver Tissue in the Common Carp (*Cyprinus carpio*) Following Vaccination Against *Aeromonas hydrophila*

Israa A. Al-Atbee^{1*}, Khalida S. Al-Niaeem² and Awatif H. Issa³

¹Department of Vertebrates, Marine Science Center, University of Basrah, Basrah, Iraq

²Department of Fisheries and Marine Resources, College of Agriculture University of Basrah, Basrah, Iraq

³Department of Pathological Analysis, College of Science, University of Basrah, Basrah, Iraq

*Corresponding Author: esraa.fadhil@uobasrah.edu.iq

ARTICLE INFO

Article History:

Received: March 18, 2025

Accepted: May 11, 2025

Online:

Keywords:

Aeromonas hydrophila,
Cyprinus carpio,
Histopathology,
Liver,
Vaccine

ABSTRACT

This study aimed to evaluate the effect of vaccination against *Aeromonas hydrophila* in common carp (*Cyprinus carpio*). The research was conducted between October 2024 and February 2025 at the Marine Science Center, University of Basrah, Iraq. Histopathological examinations of liver tissues were carried out to monitor pathological alterations and to assess the vaccine's effectiveness in reducing these changes. The histopathological results revealed notable differences among the experimental groups. In Group 1 (G1), the hepatic architecture appeared normal. In contrast, Group 2 (G2) exhibited significant vascular congestion, although hepatocytes remained relatively intact. Group 3 (G3) showed clear signs of hepatocellular necrosis. However, groups 4 (G4) and 5 (G5) displayed reduced severity of edema and necrosis. This suggests that vaccination—whether administered before infection or as repeated doses—provided partial protection. It alleviated the severity of infection by enhancing the immune response in the liver without causing substantial tissue damage. In conclusion, the vaccine against *Aeromonas hydrophila* demonstrated a clear protective effect on liver tissue. Its effectiveness was influenced by the number of doses administered and the fish's exposure to the bacteria.

INTRODUCTION

Aeromonas hydrophila is a facultative anaerobic, Gram-negative, rod-shaped bacterium common found in freshwater environment. It is recognized as a major pathogen in aquaculture, causing significant morbidity and mortality among various fish species (Semwal *et al.*, 2023). This bacterium has a significant impact on the welfare and productivity of various fish species, especially carp (*Cyprinus carpio* L.), and is therefore considered one of the main causes of disease in fish farms (Pereira, 2023; Jumma, 2024). The pathogenic nature of this bacterium is rooted in its capability to infiltrate host tissues and to dodge immune defenses, leading to a range of clinical symptoms and serious systemic infections (Hiba *et al.*, 2020; Ahangarzadeh *et al.*, 2022).

This poses a significantly economical and environment threat to the global aquacultures industry (**Igbiosa *et al.*, 2012**). Although diseases outbreaks are not always expected, weak immunity fish are particular susceptible to infections with *A. hydrophila*. Stressful aquaculture conditions, such as low oxygen levels, high organic matter content, physical injury, temperature fluctuations, overcrowding and industrial pollution can lead to immunosuppression in fish populations (**Al-Bayati *et al.*, 2020**; **Miryala & Swain, 2025**). These condition make a favorable environments for the diffusion of pathogenesis and the progression of diseases. Effective management of these environmental stresses is essential to minimize the risks associated with *A. hydrophila* outbreaks (**Semwal *et al.*, 2023**; **Jumma *et al.*, 2025**). Given that freshwater aquaculture accounts for approximately 83% of global aquaculture production, its sustainability is essential to meet the growing global demand for aquatic protein (**FAO, 2022**). Practical and strategic interventions must be prioritized to ensure long-term benefits, especially for vulnerable populations that depend on aquaculture resources.

The overuse of traditional antibiotics—such as cefotaxime, amoxicillin, erythromycin, ampicillin, amikacin, and streptomycin—has led to the emergence of antibiotic-resistant strains of *Aeromonas hydrophila* (**Lee *et al.*, 2016**; **Pauzi *et al.*, 2020**; **Tartor *et al.*, 2021**). In some instances, farmers have resorted to increasing antibiotic dosages to control infections, further accelerating the development of resistance (**Abdul Kari *et al.*, 2022**). Although some antibiotics, such as florfenicol and thiamphenicol, remain effective at lower concentrations, the persistence of resistance remains a significant challenge (**Assane *et al.*, 2019**). Alarmingly, *A. hydrophila* is responsible for nearly 90% of multidrug resistance observed in laboratory isolates, rendering conventional antibiotic treatments increasingly ineffective (**Eid *et al.*, 2022**).

In light of the rising prevalence of antibiotic resistance, the development of effective vaccines has become a cornerstone of sustainable disease control in aquaculture. Current vaccination approaches—including subunit, inactivated, live attenuated, and recombinant formulations—are supported by advances in modern biotechnology. These vaccines utilize specific antigens or whole inactivated bacterial cells to stimulate both innate and adaptive immune responses in the host (**Adams *et al.*, 2019**).

Although intraperitoneal injection remains highly immunogenic, it is labor-intensive, costly, and impractical for large-scale aquaculture operations (**Assefa *et al.*, 2018**). Oral vaccination presents a promising alternative; however, challenges related to antigen absorption and adequate immune stimulation persist. Nevertheless, several studies have reported encouraging results with oral vaccines (**Ismail *et al.*, 2016**), underscoring the need for further research into effective and practical vaccination strategies against *A. hydrophila*.

MATERIALS AND METHODS

1. Fish study

This study included 40 fish and was conducted between October 2024 and February 2025 at the Marine Science Center, University of Basrah, Iraq. The fish were randomly divided into five groups of eight individuals each:

- **Group 1 (G1):** Control group
- **Group 2 (G2):** Infected, non-vaccinated
- **Group 3 (G3):** Vaccinated with a single dose (0.002 ml/L)
- **Group 4 (G4):** Vaccinated with a double dose (0.002 ml/L), with one month between doses
- **Group 5 (G5):** Vaccinated only, not exposed to infection

2. Histopathology

Liver tissues were collected from both infected and control fish and were fixed in 10% buffered formalin for 48 hours. Tissue processing followed the method described by (Humason, 1972). Samples were dehydrated in a graded ethanol series, cleared with xylene, and embedded in paraffin. Sections (5–7 μ m thick) were prepared using a rotary microtome. The sections were mounted on glass slides, deparaffinized in xylene, rehydrated through graded alcohols, and stained with Hematoxylin and Eosin (H&E) for histological examination.

Photomicrographs were taken using a light microscope equipped with a digital camera. Analysis was performed at a total magnification of 400 \times .

3. Isolation and identification of bacterial strains

Bacteria were isolated from the liver, intestine, and kidneys of infected fish showing clinical signs of bacterial infection, including ulcers and skin hemorrhaging. Bacterial identification was carried out using the Vitek II system.

4. Inactivated vaccines against *Aeromonas hydrophila*

Inactivated vaccines were used to stimulate humoral and essential immune responses against *A. hydrophila*. These vaccines consisted of chemically killed bacterial cells and were administered at a dose of 0.002ml/ L for both single and double dosing regimens. The vaccines were effective in increasing antibody production, activating

immune-related genes, and enhancing non-specific defense mechanisms that protect fish from *A. hydrophila* infection (Shoemaker *et al.*, 2018; Vaz Farias *et al.*, 2020; Zhang *et al.*, 2023).

RESULTS

The results of the current study revealed significant histological differences among the experimental groups, underscoring the protective role of the vaccine in enhancing fish resistance to bacterial infection and minimizing tissue damage.

- **Group 1 (G1):** The hepatic architecture appeared normal, with hepatocytes arranged radially around the central vein. Cells exhibited clear boundaries and centrally located nuclei. Sinusoids were uniformly distributed, with no signs of inflammation or degeneration (Fig. 1).
- **Group 2 (G2):** Significant vascular congestion was observed, indicating an acute inflammatory response. However, hepatocytes remained relatively intact, suggesting early-stage infection or partial resistance to cellular damage (Fig. 2).
- **Group 3 (G3):** Hepatocellular necrosis was evident, indicating a more intense inflammatory response and suggesting that a single vaccine dose may not be sufficient to provide effective protection (Fig. 3).
- **Group 4 (G4):** Edema and hepatocellular necrosis were present, but to a lesser extent than in G2. This indicates that repeated vaccination provided partial protection and reduced infection severity by enhancing the immune response (Fig. 4).
- **Group 5 (G5):** Mild inflammatory changes and vascular dilation were observed, suggesting that the vaccine activated a localized immune response without causing significant tissue damage. This response is typical of effective vaccines that stimulate the immune system without inducing harmful side effects (Fig. 5).

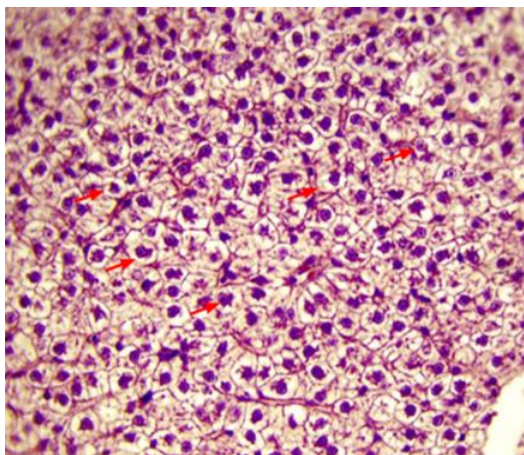


Fig. 1: The normal hepatocytes in the control group (red arrow). 400X H&E staining

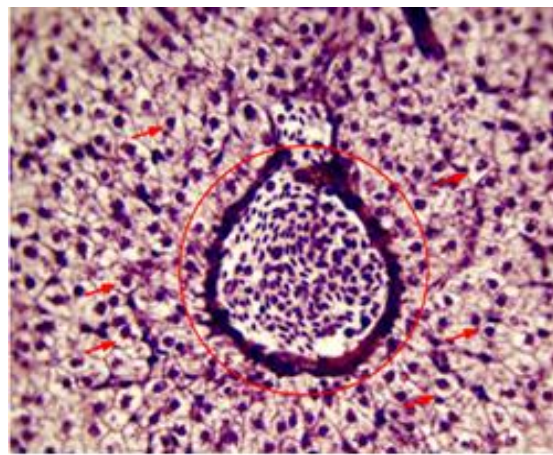


Fig. 2. Congestion blood vessel (red cycle) but normal hepatocytes in the infected non-vaccinated group (red arrows). 400X H&E staining

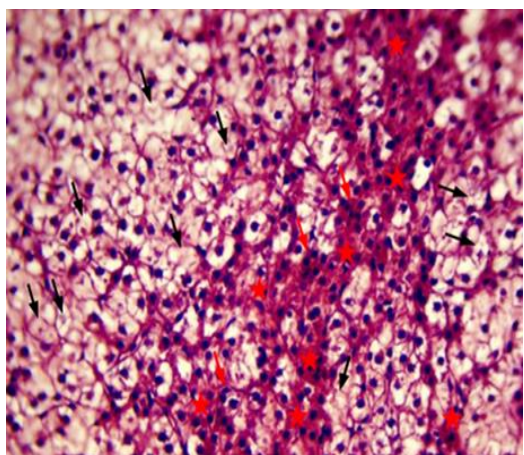


Fig. 3. Eosinophilic of hepatocytes (asterisk) and atrophy (red arrows) with necrosis (black arrows) of hepatocytes in the group vaccinated by single dose 0.002ml/L, 400X H&E staining

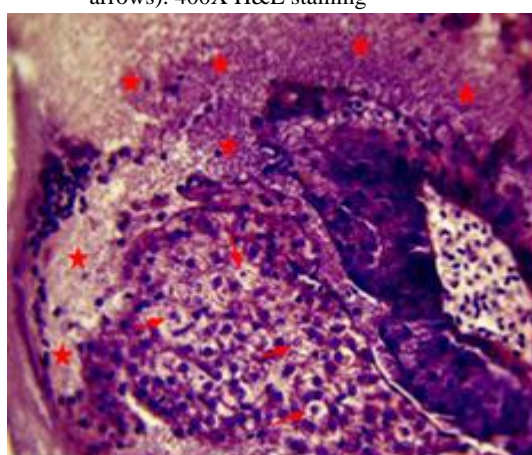


Fig. 4. The presence of edema (red asterisk), and necrosis (red arrows) of hepatocytes in the group vaccinated with by double dose 0.002ml/L. 400X H&E staining

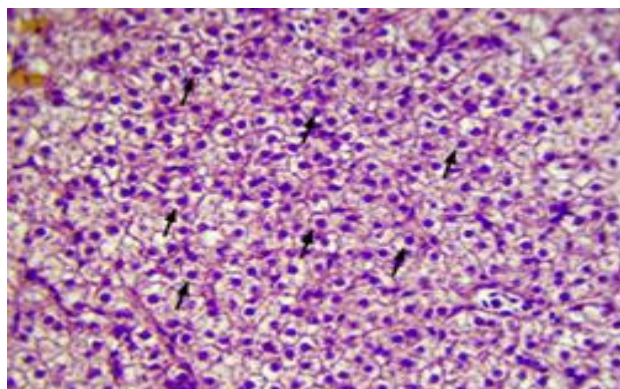


Fig. 5. The presence of edema (black asterisk) and necrosis (red arrows) and eosinophilic (red asterisk) of hepatocytes in the additional group that was vaccinated without being exposed to the infection. 400X H&E staining

DISCUSSION

Histopathological examination plays a critical role in evaluating the health status of fish (Gernhöfer *et al.*, 2001; Ruiz-Picos *et al.*, 2015). Tissue analysis is essential for identifying the pathological effects of infectious agents, as histological biomarkers reflect the overall health condition of fish in aquatic environments (Moon *et al.*, 2012; Alwan & Al-Bayati, 2020). In the current study, vascular congestion, hepatocellular necrosis, and hepatic edema were observed. These findings suggest that *Aeromonas hydrophila* secretes toxins that damage the endothelial lining of blood vessels. This result is in agreement with the findings of Chen *et al.* (2020), who reported that the liver, being the primary organ for detoxification due to its physiological role and anatomical position, is one of the most affected organs by bacterial toxins.

The liver is a highly sensitive tissue and serves as a critical organ for evaluating the impact of pollutants on fish, as illustrated in Fig. (2). Recent studies on pathogens such as *A. hydrophila* have shown alterations in normal liver structure, including dilation of blood vessels and sinusoids, as well as cellular degeneration. These findings align with those of Abdel Rahman *et al.* (2022), who reported similar histological changes in carp liver, including sinusoidal dilation attributed to the breakdown of structural proteins.

The current study also demonstrated that vaccination enhances the non-specific immune responses of common carp following infection with *A. hydrophila*. However, double vaccination appeared to have a counterproductive effect, potentially suppressing immune enhancement and reducing protection against the pathogen. This observation is consistent with the findings of Li *et al.* (2013), who noted that excessive bacterial vaccine doses may lead to the accumulation of bacterial components in internal organs, causing histological damage and toxin buildup in the liver.

In contrast, the vaccinated-only group (not exposed to infection) exhibited only mild alterations, such as slight inflammation and vascular dilation. This suggests that the vaccine elicited a localized immune response in the liver without causing significant tissue injury. Such an outcome is typical of vaccines that activate the essential immune system. These findings are in agreement with previous studies showing that vaccination effectively stimulates host immunity and that inactivated vaccines can confer protection against *A. hydrophila* infections (Zhang *et al.*, 2023; Abdullah *et al.*, 2024).

CONCLUSION

Aeromonas hydrophila can improve the immunity responses in common carp (*Cyprinus carpio*). However, the efficacy of protection appears to be dose-dependent. The study underscores the importance of establishing optimal vaccination protocols that carefully consider the number of doses administered in order to balance immune enhancement with the minimization of adverse tissue effects.

REFERENCES

- Abdel Rahman, A.N.; Shakweer, M.S.; Algharib, S.A.; Abdelaty, A.I.; Kamel, S.; Ismail, T. A. and Mahboub, H.H.** (2022). Silica nanoparticles acute toxicity alters ethology, neurostress indices, and physiological status of African catfish (*Clarias gariepinus*). *Aquac. Rep.* (23)5, 101034. <https://doi.org/10.1016/j.aqrep.2022.101034>
- Abdul Kari, Z.; Wee, W.; Mohamad Sukri, S. A.; Che Harun, H.; Hanif Reduan, M. F.; Irwan Khoo, M. and Wei, L.** (2022). Role of phytobiotics in relieving the impacts of *Aeromonas hydrophila* infection on aquatic animals: A mini-review. *Frontiers in veterinary science*, 9, 1023784. <https://doi.org/10.3389/fvets.2022.1023784>
- Abdullah, S.A.; Al-Bayati, H.H.K.; Shihab, T.J., Sultan, M. and Jumaa, Q. S.** (2024). Immunogenicity of culture filtrated proteins and whole-cell killed formalin of *Listeria monocytogenes* to induced cellular immune response in vivo. *Open veterinary journal*, 14(12), 3581–3598. <https://doi.org/10.5455/OVJ.2024.v14.i12.40>
- Adams A.** (2019). Progress, challenges and opportunities in fish vaccine development. *Fish Shellfish Immuno.* 90:210–4. <https://doi.org/10.1016/j.fsi.2019.04.066>
- Ahangarzadeh, M.; Ghorbanpour, N. M.; Peyghan, R.; Houshmand, H.; Sharif Rohani, M. and Soltani, M.** (2022). Detection and distribution of virulence genes in *Aeromonas hydrophila* isolates causing infection in cultured carps. *Veterinary research forum: an international quarterly journal*, 13(1), 55–60. <https://doi.org/10.30466/vrf.2020.115998.2761>
- Al-Bayati, H.H.; Hussein, F.A.; Thamer, I.K. and Abdullah, B.A.** (2020). Effects of Coconut oil and fusidic acid extract in alternative traumatic wound healing in RATS model. *Systematic Reviews in Pharmacy*. 11(11), 208–213. <https://doi.org/10.31838/srp.2020.11.30>
- Aljoburi, A.; Jumma, Q. and Al-shammari, S.** (2024). Effects of different vaccination methods against newcastle disease on immune response and some blood parameters in local chicken (*gallus gallus domesticus*) in shirqat city. *Assiut veterinary medical journal*, 70(183), 519-530. Doi: [10.21608/avmj.2024.297170.1280](https://doi.org/10.21608/avmj.2024.297170.1280)
- Alrudainy, A. J. and Jumaa, Q. S.** (2016). Effect of Magnitized Water On Common Carp *Cyprinus Carpio* Rearing In Different Salinity Concentrations. *Iraqi Journal Of Agricultural Sciences*.47(2),.646-655. DOI: <https://doi.org/10.36103/ijas.v47i2.611>
- Alshumary, H.; jumma, Q.; Khorsheed, H. and alKaisi, B.** (2024). Assessment of The toxic Effect of Environmental Pollution by 2 ,3 ,7 ,8 - Tetrachlorodibenzo-p-

- dioxin (TCDD) on The Female Reproductive System by Pathological and Biochemical Assay in Albino Female Rats. *Egyptian Journal of Veterinary Sciences*, 55(5), 1409-1415. Doi: [10.21608/ejvs.2024.254722.1721](https://doi.org/10.21608/ejvs.2024.254722.1721)
- Alwan, M.J. and Al-Bayati, H.** (2020). Immunohistopathological and immunological evaluation of listeria nanoparticle vaccine during the first and third semester in the pregnancy rat model. *Plant Archives*. 20 (2), 2016-2025. <https://www.plantarchives.org/SPL%20ISSUE%2020-2/335>.
- Assane, I.M.; Gozi, K.S.; Valladão, G.M.R. and Pilarski, F.** (2019). Combination of antimicrobials as an approach to reduce their application in aquaculture: Emphasis on the use of thiamphenicol/florfenicol against *Aeromonas hydrophila*. *Aquaculture*. 507, 238–245. <https://doi.org/10.1016/j.aquaculture.2019.04.021>
- Assefa, A. and Abunna, F.** (2018). Maintenance of Fish Health in Aquaculture: Review of Epidemiological Approaches for Prevention and Control of Infectious Disease of Fish. *Veterinary medicine international*. 5432497. <https://doi.org/10.1155/2018/5432497>
- Bashar, S. N.; Qusai, S. J.; Muthanna, S.; Raghad, Z. S.; Khalid, A. H. and Ali, A. A.** (2025). Preventive and Ameliorative Role of Lactoferrin in Improving Blood, Lipid and Liver Profiles Toward Immune Homeostasis in Lipopolysaccharides (LPS) Induced Dysregulation of Bio-Vital Parameters in the Common Carp (*Cyprinus carpio*). *Egyptian Journal of Aquatic Biology and Fisheries*, 29(2), 1173-1180. <https://doi.org/10.21608/ejabf.2025.419336>
- Chen, J.; Liua, N.; Zhanga, H.; Zhaoa, Y. and Caob, X.** (2020). The effects of *Aeromonas hydrophila* infection on oxidative stress, nonspecific immunity, autophagy, and apoptosis in the common carp. *Dev Comp Immunol*, 105: 1-9. <https://doi.org/10.1016/j.dci.2019.103587>
- Eid, H. M.; El-Mahallawy, H. S.; Shalaby, A. M.; Elsheshtawy, H. M.; Shetewy, M. M. and Hussein Eidaroos, N.** (2022). Emergence of extensively drug-resistant *Aeromonas hydrophila* complex isolated from wild Mugil cephalus (striped mullet) and Mediterranean seawater. *Veterinary world*, 15(1), 55–64. <https://doi.org/10.14202/vetworld.2022.55-64>
- FAO.** The State of World Fisheries and Aquaculture (SOFIA); FAO: Rome, Italy, 2022; 266.
- Gernhöfer, M.; Pawert, M.; Schramm, M.; Müller, E. and Triebkorn, R.** (2001). Ultrastructural biomarkers as tools to characterize the health status of fish in contaminated streams. *Journal of Aquatic Ecosystem Stress and Recovery*, 8, 241-260. <https://doi.org/10.1023/A:1012958804442>
- Hiba, A.S.; Siham, A.W.; Hassan, H. and Maythaem, A.I.** (2020). Evaluation the effect and efficacy of lidocaine on healing of skin wound in rabbits. *Systematic Reviews in Pharmacy*. 11(12), 1368-1372. <https://doi.org/10.31838/srp.2020.12.203>

- Humason, G.L.** (1972) Animal tissue techniques. 3rd Edition, W.H. Freeman and Company, San Francisco.
<https://www.scirp.org/reference/referencespapers?referenceid=102968>
- Hussein, A. and Jumma, Q.** (2024). Diagnosis of Infectious Bronchitis Infection in Broiler Chicken Farms in Salah Al-Din Governorate. *Egyptian Journal of Veterinary Sciences*, 55(6), 1619-1626. Doi: [10.21608/ejvs.2024.262773.1780](https://doi.org/10.21608/ejvs.2024.262773.1780)
- Igbinsosa, I. H.; Igumbor, E. U.; Aghdasi, F.; Tom, M. and Okoh, A. I.** (2012). Emerging Aeromonas species infections and their significance in public health. *The ScientificWorldJournal*. 625023. <https://doi.org/10.1100/2012/625023>
- Ismail, M. S.; Siti-Zahrah, A.; Syafiq, M. R.; Amal, M. N.; Firdaus-Nawi, M. and Zamri-Saad, M.** (2016). Feed-based vaccination regime against streptococcosis in red tilapia, *Oreochromis niloticus* x *Oreochromis mossambicus*. *BMC veterinary research*, 12(1), 194. <https://doi.org/10.1186/s12917-016-0834-1>
- Jumma, Q.S.** (2024). Detection of ESBL E. coli That Carried STX1 and STX2 Form Common Carp (*Cyprinus carpio*) in Salhaldeen Province, Egypt. *J. Vet. Sci.* 55(4): 1165-1170. <https://doi.org/10.21608/EJVS.2024.255648.1728>
- Jumma, Q. S.; Abd, A.A. and Al-Juhaishi, O. A.** (2025). Effects of Sulpiride on the Reproductive System of Male Rats after Puberty. *World Vet. J.* 15(1): 42-48. <https://dx.doi.org/10.54203/scil.2025.wvj5>
- Lee, S. W.; Sim, K. Y.; Wendy, W. and Zulhisyam, A. K.** (2016). Peperomia pellucida leaf extract as immunostimulator in controlling motile aeromonad septicemia due to *Aeromonas hydrophila* in red hybrid tilapia, *Oreochromis* spp. farming. *Veterinary world*, 9(3), 231–234. <https://doi.org/10.14202/vetworld.2016.231-234>
- Li, M.; Mai, K.; Ai, Q.; He, G.; Xu, W. and Zh, W.** (2013). Effects of dietary grape seed oil and linseed oil on growth, muscle fatty acid composition and expression of putative $\Delta 5$ fatty acyl desaturase in abalone *Haliotis discus hannai* Ino. *Aquaculture*, 406-407. <https://doi.org/10.1016/j.aquaculture.2013.05.013>
- Miryala, K. R. and Swain, B.** (2025). Advances and Challenges in *Aeromonas hydrophila* Vaccine Development: Immunological Insights and Future Perspectives. *Vaccines*, 13(2), 202. <https://doi.org/10.3390/vaccines13020202>
- Moon, M. K.; Kim, M. J.; Jung, I. K.; Koo, Y. D.; Ann, H. Y. and Park, Y. J.** (2012). Bisphenol A impairs mitochondrial function in the liver at doses below the no observed adverse effect level. *Journal of Korean medical science*, 27(6), 644–652. <https://doi.org/10.3346/jkms.2012.27.6.644>
- Oday, A. A.; Firas, A. H.; Qusai, S. J. and Marwa, A. H.** (2024). Histological Investigation of the Skin Structure in the Common Carp (*Cyprinus carpio*) and the Catfish (*Silurus triostegus*): Aquatic Environment Adjustment". *Egyptian Journal of Aquatic Biology and Fisheries*. 28(6), 2219-2228. Doi: [10.21608/ejabf.2024.400587](https://doi.org/10.21608/ejabf.2024.400587)

- Pauzi, N. A.; Mohamad, N.; Azzam-Sayuti, M.; Yasin, I. S. M.; Saad, M. Z.; Nasruddin, N. S. and Azmai, M. N. A.** (2020). Antibiotic susceptibility and pathogenicity of *Aeromonas hydrophila* isolated from red hybrid tilapia (*Oreochromis niloticus*×*Oreochromis mossambicus*) in Malaysia. *Veterinary world*, 13(10), 2166–2171. <https://doi.org/10.14202/vetworld.2020.2166-2171>
- Pereira, W. A.; Reis, I.; Villasante, A.; Ramírez, C.; Franco, S.; Mendonça, C. M. and de Souza Oliveira, R. P.** (2023). Advances in Tilapia farming: Statistical Analysis of the Use of Probiotics and Assessment of their Potentials and Challenges. <https://doi.org/10.20944/preprints202311.0156.v1>
- Ruiz-Picos, R. A.; Sedeño-Díaz, J. E. and López-López, E.** (2015). Histopathological indicators in fish for assessing environmental stress. *Environmental Indicators*, 663-675. https://link.springer.com/chapter/10.1007/978-94-017-9499-2_38#citeas
- Sabah, M.A.; Qusai, J. and Ali, A.** (2024). Oxidative Stress and Blood Parameters Affected by Carbaryl Insecticide in *Cyprinus carpio*. *Egyptian Journal of Aquatic Biology and Fisheries*, 28(6):2195-2201. <https://doi.org/10.21608/ejabf.2024.400585>
- Semwal, A., Kumar, A., & Kumar, N.** (2023). A review on pathogenicity of *Aeromonas hydrophila* and their mitigation through medicinal herbs in aquaculture. *Heliyon*, 9(3), e14088. <https://doi.org/10.1016/j.heliyon.2023.e14088>
- Shoemaker, C.A.; Mohammed, H.H.; Bader, T.J.; Peatman, E. and Beck, B.H.** (2018). Immersion vaccination with an inactivated virulent *Aeromonas hydrophila* bacterin protects hybrid catfish (*Ictalurus punctatus* X *Ictalurus furcatus*) from motile *Aeromonas* septicemia. *Fish Shellfish Immunol.* 82, 239–242. <https://doi.org/10.1016/j.fsi.2018.08.040>
- Tartor, Y.H.; El-Naenaeey, E.-S.Y.; Abdallah, H.M.; Samir, M.; Yassen, M.M. and Abdelwahab, A.M.** (2021). Virulotyping and genetic diversity of *Aeromonas hydrophila* isolated from Nile tilapia (*Oreochromis niloticus*) in aquaculture farms in Egypt. *Aquaculture*. 541, 736781. <https://doi.org/10.1016/j.aquaculture.2021.736781>
- Vaz Farias, T.H.; Arijo, S.; Medina, A.; Pala, G.; da Rosa Prado, E.J.; Montassier, H.J.; Pilarski, F. and Antonio de Andrade Belo, M.** (2020). Immune responses induced by inactivated vaccine against *Aeromonas hydrophila* in pacu, *Piaractus mesopotamicus*. *Fish Shellfish Immunol.* 101, 186–191. <https://doi.org/10.1016/j.fsi.2020.03.059>
- Zhang, M.; Zhang, T.; He, Y.; Cui, H.; Li, H. and Ding, Z.** (2023). Immunogenicity and protective efficacy of OmpA subunit vaccine against *Aeromonas hydrophila* infection in *Megalobrama amblycephala*: An effective alternative to the inactivated vaccine. *Frontiers in immunology*, 14, 1133742. <https://doi.org/10.3389/fimmu.2023.11>