

Therapeutic Potential of Chitosan Dressing for Stab Injury Wound Healing in an Earthworm Model

Asmaa F.A. Dawood^{1, 2}, Shereen Mahmoud Refaie¹, Shahina Khan¹,
Shahzeen Fatima Hussaini¹, Fatma El-Zahraa A. Abd El-Aziz^{3*} 

¹Department of Biomedical Science, College of Medicine, King Faisal University, Alhasa, Saudi Arabia

²Department of Histology, Faculty of Medicine, Assiut University, Assiut, Egypt

³Zoology and Entomology Departments, Faculty of Science, Assiut University, 71516 Assiut, Egypt

*Corresponding Author: fatma.abdelgalil1@science.aun.edu.eg,

 <https://orcid.org/0000-0001-7260-7598>

ARTICLE INFO

Article History:

Received: Dec. 22, 2023

Accepted: Jan. 7, 2024

Online: Feb. 1, 2024

Keywords:

Chitosan dressed wound,
Earthworms,
Skin,
Wound healing

ABSTRACT

The use of natural materials in modern times is one of the interests of science. In recent years, there has been a rapid and exciting development in the use of biologically- based organic materials, for example, innovative drug treatments, with a focus on addressing, diabetic wound healing, cancer, and infectious diseases. Focus on tissue responses, chitosan has been registered as a representative lightweight organic material for its distinctive properties, such as formability, processability, non-toxicity, and chemical activity, in addition to its compatibility with chemical flame and chemical sensitivity. Most importantly, it has antimicrobial activity and promotes wound healing. In this work, the applications of chitosan were used as a wound dressing. Optimized chitosan was estimated for wound healing through topical cream application for three successive days on surgical cuts made in (*Lumbricus castaneus*) earthworms, as an alternative for human skin. The outcomes showed conspicuous decreases in both wound closure and re-epithelialization duration in chitosan-treated earthworms as evident through macroscopic examination and thorough histological scrutiny utilizing light and electron microscopy, in comparison with the control group. In summation, these findings posit that a wound dressing in chitosan holds promise as a catalyst for wound healing. Future endeavors will delve into scrutinizing the intricate mechanisms underlying this influential phenomenon.

INTRODUCTION

Diverse origins contribute to skin wounds, stemming from surgical procedures, burns, abrasions, chronic ulcers like those associated with diabetes, and various traumatic incidents. The intricate process of skin wound healing, influenced by a multitude of factors, can be expedited through meticulous wound care employing effective agents (Abd El-Hack *et al.*, 2020). The materials applied to wounds must meet specific criteria—being optimal, biodegradable, and widely applicable, with the ability to maintain a moist environment, control bleeding, and absorb exudates (Abd El-Hack *et al.*, 2020).

Chitosan, an inherent cationic polysaccharide composed of (1 → 4)-2-amino-2-deoxy-β-d-glucan, stands as the deacetylated form of chitin (Hosseinnejad & Jafari, 2016). Noteworthy as the first and second most abundant polymers, cellulose and chitin, respectively, garner significant interest due to the biopolymeric nature of chitin (Abdel-Rahman *et al.*, 2015). Chitin finds its origins in various sources, including crustacean shells, microbial cell walls (fungi or algae), insect exoskeletons, and mollusk shells (Yeul & Rayalu, 2013; Kaur & Dhillon, 2015; Islam *et al.*, 2017; Philibert *et al.*, 2017). The ubiquity and versatility of chitin have made it a focal point of scientific inquiry for many years.

Numerous sources have shed light on the pivotal role played by chitosan and its derivatives in the realm of skin wound care, elucidating a spectrum of pharmacological actions. These encompass desirable traits such as hemostatic capabilities (Khan & Mujahid, 2019), antibacterial prowess, anti-inflammatory attributes, and the ability to stimulate skin regeneration (Mohan *et al.*, 2020). The material's excellence is further underscored by its superior biocompatibility and biodegradability, as established by Li *et al.*, (2020). Notably, chitosan boasts commendable water-absorption and water-retention properties, along with molecular chains adorned with amino (NH₂) and hydroxyl (OH) groups. This molecular configuration allows for the grafting of diverse groups and chemical components, thereby enhancing specific biological functions (Abd El-Hack *et al.*, 2020).

In the context of this inquiry, we embark on an exploration delving into the multifaceted functions and underlying mechanisms of chitosan as a material for wound care. Its capabilities span the inhibition of bacterial infections, arrest of bleeding, and the facilitation of granulation tissue growth. Additionally, the study navigates through the applications of chitosan, extending into the realm of hydrogels for advanced wound treatment. The intricate narrative of this investigation is encapsulated in the illustrative journey outlined in Fig. (1), underscoring the diverse dimensions of chitosan's contributions to the field of wound care.

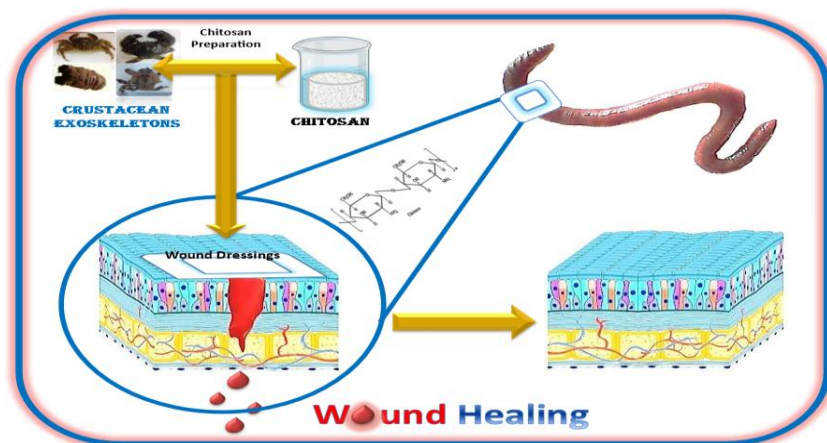


Fig. 1. The investigation flow of the whole article

The earthworm, belonging to phylum Annelida and the family Lumbricidae, is one of the first species to develop immunological memory and recognition. Like other complex invertebrates, earthworms produce a variety of leukocytes, create and secrete a number of immune protective chemicals.

They own innate immunity, as well as a few capabilities related to the adaptive immunity (Cooper *et al.*, 1999). In 1340 AD, the use of earthworm as a medication was documented for the first time, as well as in folk medicine (Stevenson, 1930; Reynolds & Reynolds, 1972). Earthworms have been traditionally utilized to cure a variety of diseases throughout Asia. The earthworms have also been widely employed in Chinese medicine, and pharmaceutical research on their properties has been ongoing for a long period.

The impacts of earthworms have started in tandem with the development of biochemical technologies (Cooper *et al.*, 2004). Many bioactive compounds that could be used as drugs have been discovered in earthworms. These compounds had a variety of properties, including fibrinolytic, anticoagulant, anticancer, and antibacterial. Hence, it might be used to treat a variety of ailments (Chen *et al.*, 2007; Cooper *et al.*, 2012; Wangchuk, 2018).

Throughout history, *Lumbricus rubellus*, commonly known as earthworms, has carved a unique niche in medicinal practices, serving as adjuvant therapy or alternative medicine for various ailments. Its historical applications span a spectrum of diseases, encompassing conditions such as typhoid fever, staphylococcus infections, and dermatitis. Numerous scientific studies substantiate the antibacterial efficacy of *Lumbricus rubellus*, shedding light on its potential therapeutic benefits. Interestingly, certain traditional uses of earthworms as home remedies find validation in human applications, adding a layer of credibility to their historical medicinal role (Sara *et al.*, 2023).

Earthworms were utilized in this work as an alternative human skin model based on claimed similarities to human skin, where both contain triene and tetraene sterols, as documented in the literature (Albro *et al.*, 1997; Misra *et al.*, 2005; Abd El-Aziza & Ali, 2021). While few researchers, such as Abd Ellah *et al.* (2019), Abd El-Aziz *et al.* (2022) and Salem *et al.* (2022) have embarked on the investigated wound healing.

MATERIALS AND METHODS

i. Preparation of chitosan

Marine crustaceans (crabs, lobsters, crayfish shrimps) were obtained from the Mediterranean Sea. The collected crustacean exoskeletons were repeatedly washed to remove dust and other extraneous materials, as well as to remove the protein; dried shells of crustaceans were treated with NaOH then dried at room temperature. After centrifugation to separate NaOH insoluble fraction, repeated washings with distilled water were performed until the pH was neutral. Deproteinized shells were added to dilute

HCl to remove minerals. Subsequently, the acid insoluble fraction was separated by centrifugation. Washing with distilled water was performed to get rid of acids. Afterward, samples were dried for a day to produce chitin, which was slightly pink in color. Samples were washed with oxalic acid solution, then grinded and sieved several times to produce purified chitin.

ii. In vivo evaluation of chitosan in earthworms wound healing

We used earthworms as a human skin model for *in vivo* evaluation of chitosan on wound healing.

iii. Treatment of earthworms

The field was scavenged for earthworms (*Lumbricus castaneus*). The samples were taken to the Department of Zoology's laboratory, where the worms were kept for two weeks under research facility settings (25– 28°C, 12 hours day, and 12 hours night). Worms were kept in plastic boxes filled with damp soil, and the soil was supplemented with dried cattle manure to provide food for the worms. A sterile medical scalpel was used to make a stab injury wound in the worms, in groups II and III.

Group I: Normal worm left without injury wound.

Group II: Earthworms with received vasillen.

Group III: Earthworms were received vasillen mixed with chitosan; the mixture was placed on a small piece of filter paper and covered with a piece of gauze for making wound dressings.

iv. Measurement of wound area

Every day the wound area was measured to evaluate the rate of healing in the wound area.

v. Histological examination

Upon the conclusion of the experiment, coelomic cell smears were meticulously prepared on clean slides. These smears underwent fixation with absolute methanol for a duration of 10 seconds. Subsequently, the slides were left to dry at room temperature. The staining process involved hematoxylin and eosin (H&E), followed by a gradual dehydration series using increasing levels of alcohol (30, 50, 70, 90%, and absolute). The final step encompassed purification in xylene and permanent mounting utilizing DPX, following the method outlined by **Pascoe and Gatehouse (1986)**. Rigorous examination and photographic documentation were carried out on the prepared slides for the anterior wound portion of each specimen, in adherence to the protocol detailed by **Drury and Wallington (1980)**. Fixation was performed using neutral formalin for subsequent histological analysis. Longitudinal and cross-sections with a thickness of 6µm were meticulously prepared, and both were subjected to staining with Masson's trichrome. The resulting sections of the body wall were scrutinized under a light microscope to glean insights for the histological examination (**Bancroft & Gamble, 2008**).

iv. Ultrastructural examination

The research was carried out at Assiut University's Electron Microscopy Unit.

- **Preparation for semithin sections**

The earthworms' groups were first fixed in 4% cold glutaraldehyde, then washed three or four times (20min each) in phosphate buffer (pH 7.2). They were postfixed in 1% osmium tetroxide (OsO₄) for two hours, and then rinsed four times in the same buffer.

The process of dehydration involved progressively raising the ethyl alcohol content. Tissue samples were immersed in propylene oxide for 30min to remove any traces of alcohol. Subsequently, they were placed in propylene oxide plus Be (submerged in Epon 812, 1:1, v/v, for 4 hours) for a further 30 minutes. Following the tissue insertion, blocks were formed into capsules, along with the embedding mixture, and they were polymerized for two days at 60°C in the oven. Using a LKB ultramicrotome, semithin pieces with a thickness of 0.5µm were cut and stained with toluidine blue (**Gupta, 1983**).

- **Preparation for transmission electron microscopy (TEM)**

After tissue localization testing on semithin components, ultra thin parts were manufactured as needed. Incredibly thin portions (between 50 and 80nm) were cut using a Leica AG ultramicrotome and stained with lead citrate and uranyl acetate. Sections from several earthworm species were analyzed using a TEM (JEOL, 100 CXII) running at 80kV. A photoshop software was used to acquire, recreate, and evaluate electron micrographs of semithin regions. Micrographs were used to display the findings.

- **Ethical statements**

The earthworms' experiments received ethical approval from the Faculty of Veterinary Medicine's ethical committee at Assiut University, granted under the official license IRB. Under the no. (06/2023/0149).

RESULTS

1. Macroscopic observation

This study vividly illustrated remarkable advancements in the wound healing process through the application of chitosan as a wound dressing. Notably, there were no worm fatalities observed throughout the experiment. On the initial day post-injury in group II, indications such as hemorrhage, edema, redness, and exudation around the wound area were apparent. Group III, treated with chitosan, exhibited the earliest coagulation after treatment. Furthermore, in stark contrast to the more than two weeks required for normal healing in group II, group III (subjected to chitosan treatment) showcased a remarkably accelerated healing process, with wound closure and re-epithelialization achieved in just five days (Fig. 2). This underscores a significant reduction in the duration of the wound closure and re-epithelialization compared to the natural healing process in the untreated group.

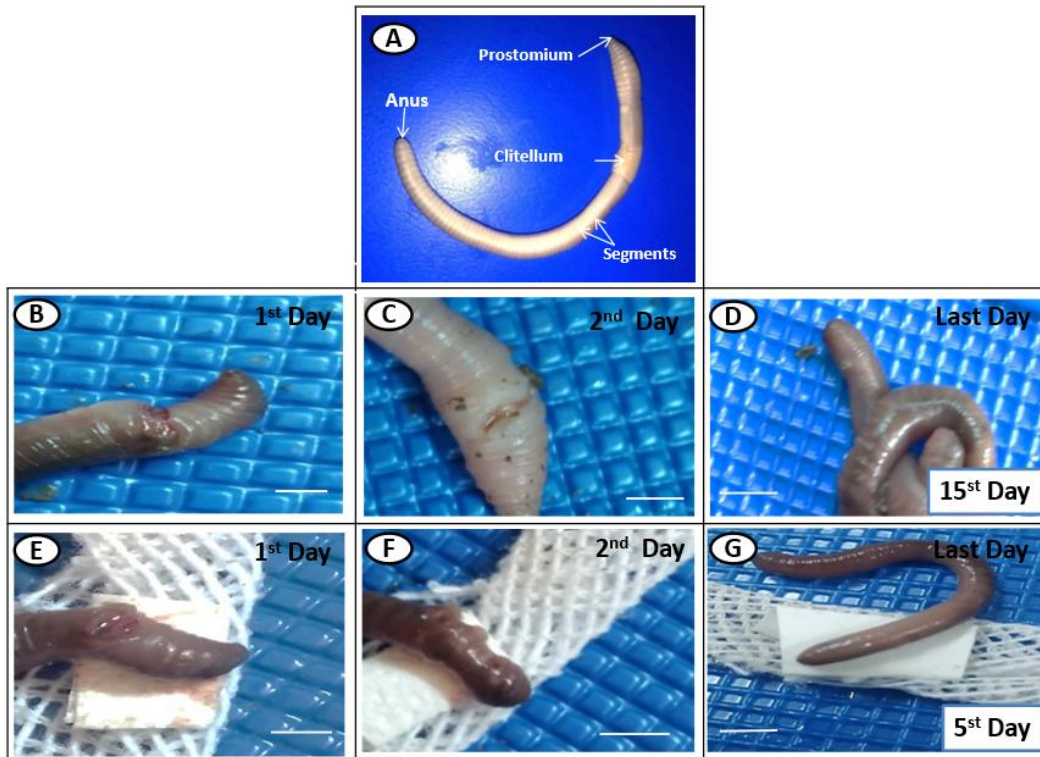


Fig. 2. Macroscopic observation of the different groups of earthworms (*Lumbricus castaneus*) stab injury wound showing: (A) Normal worms left unjured, (B, C, D) Worms receiving plain vasillan, and (E, F, G) Worms that received chitosan

2. Histological observation

i. Earthworm skin analysis

Upon scrutinizing the skin of earthworms, a meticulously structured composition emerges, comprising the cuticle, epidermal layer, and longitudinal and circular layers, delineating its layered complexity. By the fifth day of the experiment, transverse sections across the body wall of control worms (groups I and III) revealed the normal arrangement of the epidermal, longitudinal, and circular muscles (Fig. 3A, D). Conversely, transverse sections from worms in groups II and III on the initial day exhibited indications of wounds, bleeding, and inflammation (Fig. 3B). Within the second group, encompassing both untreated and vaseline-treated specimens, vacuolization and hyperplasia of epithelial cells were evident, accompanied by degeneration of circular and longitudinal muscles. Notably, the epidermal layer remained unchanged throughout the healing period, while a reduction in longitudinal thickness and circular muscles was observed (Fig. 3C). In contrast, the third group, treated with chitosan, displayed transverse sections depicting the nearly complete disappearance of inflammatory cells. The body wall showcased an intact composition of circular, human, and longitudinal muscles, underscoring the healing effects of chitosan treatment (Fig. 3D).

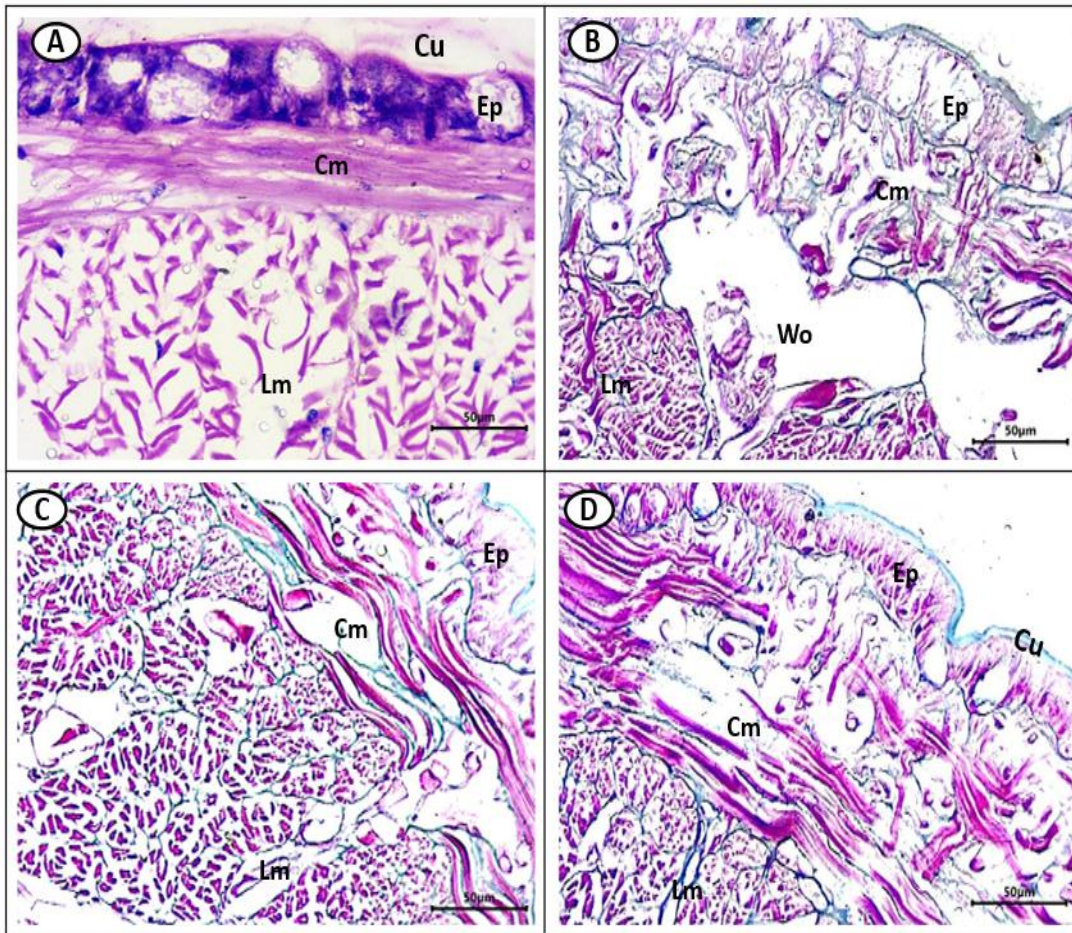


Fig. 3. Transverse sections of segments from the anterior region of the different groups of earthworms (*Lumbricus castaneus*) stab injury wound showing: (A) The control, normal worms left unwound, (B) Worms immediately create a stab injury wound, (C) Worms that received plain vasillan, and (D) Worms that received chitosan. (Magnification x400. Sections cut 6µm stained with Masson's trichrome stain, (Cu) The cuticle, (Ep) Epidermis, (Cm) Circular muscle, (Lm) Longitudinal muscle, and (Wo) wound)

ii. Coelomic cell

The coelomic cells of natural earthworms (group I) exhibited a distinctive categorization based on cytoplasmic staining, revealing two primary types: Acidophilic cells and basophilic cells. These cells display variations, including agranulated and granulated features, peripheral and central nuclei, as well as numerous vacuoles or pseudopodia. In the case of earthworms with injured wounds (group II), coelomic cells tend to aggregate in clusters, accompanied by nucleus division and the presence of numerous cell fragments. Notably, a decrease was detected in the number of vacuolated cells.

Conversely, earthworms treated with chitosan (group III) displayed a notable reduction in wound-related issues, and their coelom cells resemble those of normal worms, indicating a significant improvement in cellular characteristics (Fig. 4).

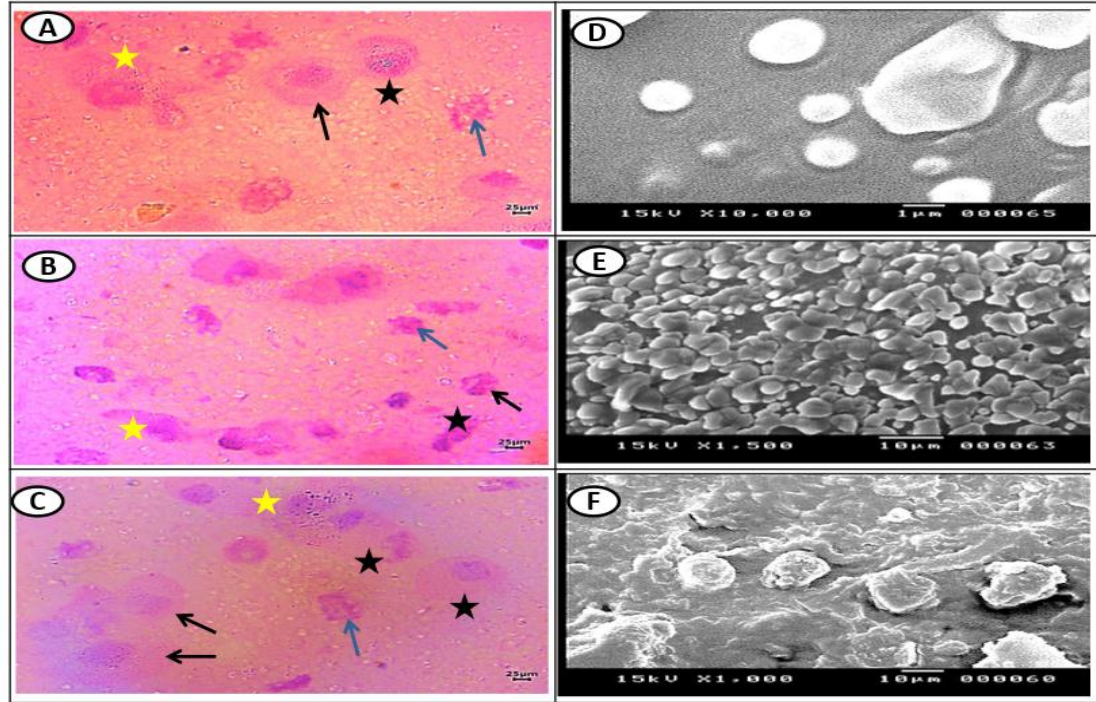


Fig. 4. Photomicrograph of acidophilic coelomic cells and Scanning electron microscope of the different groups of earthworms (*Lumbricus castaneus*) stab injury wound : (A, D) Normal worms were left unwound, (B, E) Worms that received plain vasillan, (C, F) Worms that received chitosan. Coelomic cells with central nuclei (black arrow), vacuolated cells (blue arrow), peripheral nuclei (black star), and pseudopodia (yellow star). (H&E stains)

iii. Scanning electron microscopy observation (SEM)

Scanning electron microscopy (SEM) was employed to examine the wound surface and assess the regeneration of epidermal morphology at the site of stab injuries treated with chitosan. Remarkably, in group III, the wound surfaces exhibited complete healing within five days of chitosan application, showcasing a regenerated epidermis closely resembling that of the normal group. Additionally, a conspicuous crust layer became apparent. Even after 15 days, the injury wound surface in group III was nearly healed although the formation of the crust coat was not entirely complete (Fig. 5).

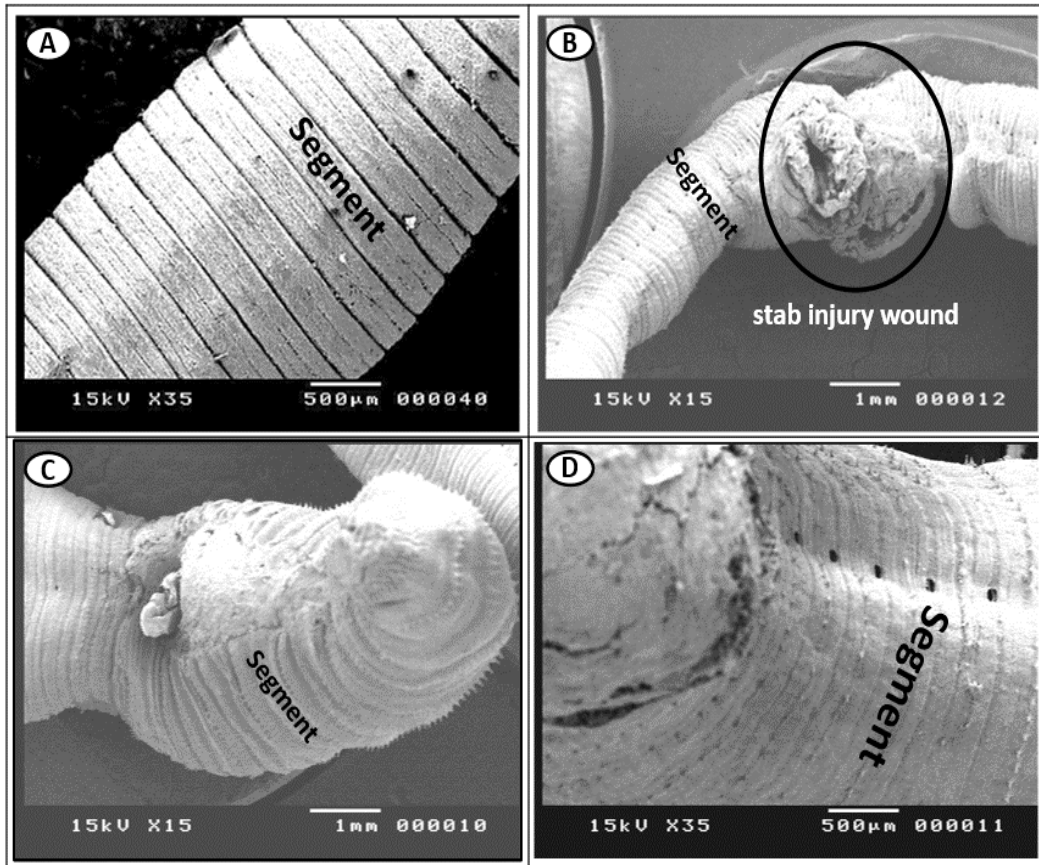


Fig. 5. Scanning electron microscope of an earthworm's skin of the different groups showing: (A) The control , normal worms left unwound, (B) Worms immediately creating a stab injury wound, (C) Worms that received plain vasillan, and (D) Worms that received chitosan

iv. Semithin sections observation

In the semithin sections, the photomicrograph of earthworms in group I showcased normal structures, encompassing the entire cuticle, epidermis, and subsequent circular and longitudinal muscles. In the untreated group II, which only received vaseline, a return to normal structure was observed after 15 days. However, the semithin study revealed structural losses, indicating a tendency toward maturation of additional glandular epithelium. This was accompanied by the breakdown of the cuticular layer, ectodermal layer, and the development of spaces between the longitudinal muscles. Semithin sections of group III demonstrated the healing of wounds and a reduction in inflammatory cells. Notably, earthworms receiving 15mg of chitosan exhibited accelerated wound healing by the fifth day, displaying the complete structure of the epidermis, circular, and longitudinal muscles (Fig. 6).

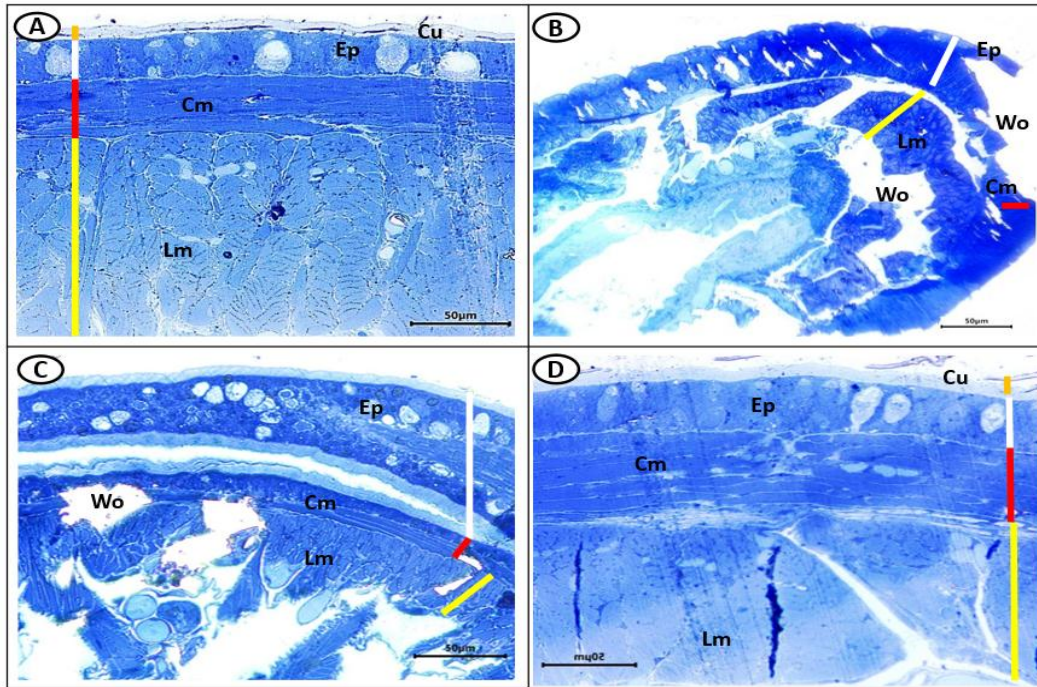


Fig. 6. Semi-thin section of the different groups of earthworms (*Lumbricus castaneus*) stab injury wound showing: (A) The control, normal worms left unwound, (B) Worms immediately create a stab injury wound, (C) Worms that received plain vasillan, and (D) Worms that received chitosan. (Toluidine blue stain. (Cu) The cuticle orange, (Ep) Epidermis white, (Cm) Circular muscle red, (Lm) Longitudinal muscle yellow, and (Wo) Wound

v. Transmission electronic microscopy observation (TEM)

The semithin section photomicrographs of earthworms unveiled intriguing findings. In the untreated group II, a span of 15 days showcased a return to normal architecture, with the circular and longitudinal muscles maintaining their integrity. Conversely, group III, examined after just five days, exhibited what appeared to be normal architecture and intact circular and longitudinal muscles. However, a closer inspection revealed a slightly diminished quality compared to the typical state. The breakdown of the cuticular membrane, ectodermal layer, and an increase in voids between the longitudinal muscles were evident, indicating structural alterations. Remarkably, a semithin section from the first day highlighted a loss of architecture and a propensity to generate an excess of glandular epithelium. Proximity to the circular and longitudinal muscle group V confirmed the proliferation of glandular cells and erosion within the ectodermal layer of the body wall, leading to cell discontinuation through narrow to large gap junctions. This may be attributed to necrosis, depending on the impact of the cut. The ultrastructural analysis of the cuticle revealed a breakdown initiation, with the dermis and circular muscles exhibiting severe necrosis. Circular muscles were completely destroyed, the

intercellular matrix appeared edematous and loose, and there was evidence of minute vessel expansion, new capillaries formation, and fibroblast proliferation (Fig. 7).

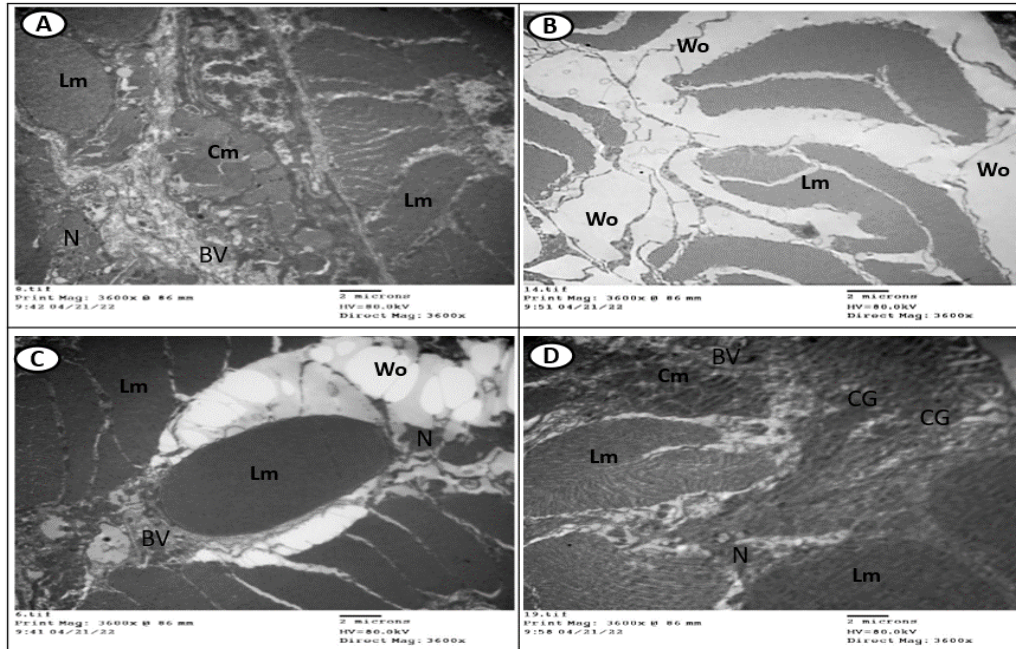


Fig. 7. Transmission electron micrographs of earthworm's skin of the different groups showing: (A) The control, normal worms left unwound, (B) Worms immediately create a stab injury wound, (C) Worms that received plain vasillan, and (D) Worms that received chitosan. (BV) Blood vessel, (Cm) Circular muscle, (Ep) Epidermis, (CG) Chitosan granules, (Lm) Longitudinal muscle, (N) Nucleus, (Wo) Wound

DISCUSSION

Our results suggest that chitosan may be the best choice for the wound healing. Following the initial injury, a symphony of morphological responses unfolded on the first day, featuring hemorrhage, edema, redness, and exudation around the wound site across all groups subjected to surgical incisions (Groups II and III). While group II, left untreated and exposed to vasillan, languished in a protracted healing process spanning over two weeks, group III, treated with chitosan, exhibited a remarkable expedited recovery, accomplishing normal healing within a mere five days. This accelerated wound healing is a novel revelation, shedding light on the potent wound-repairing properties of chitosan. The observed swiftness in wound recovery in group III can be attributed to the presence of proteins with robust antimicrobial capabilities, effectively countering a broad spectrum of pathogenic bacteria while fostering cell proliferation (Gomes *et al.*, 2011). Notably, the treatment induced a significant reduction in both wound closure and

reepithelialization periods compared to the normative healing duration (**Samuel *et al.*, 2011; Kumari *et al.*, 2013**).

Chitosan, a natural polymer with versatile applications, serves as a carrier for pharmaceutical drugs, cells, genes, and proteins (**Hosseinnejad & Jafari, 2016; Cao *et al.*, 2019; Garg *et al.*, 2019; Verma *et al.*, 2022**). Additionally, it serves as the foundational material for 3D-printed scaffolds in tissue engineering endeavors (**Zhou *et al.*, 2020**). Moreover, it is known for its biodegradability and non-toxic nature, chitosan effectively delivers biological entities without triggering an immune response (**Hoemann & Fong, 2017**). Hence, in our wound healing approach, we utilized chitosan as the dressing material.

Examining the transmission electron microscopy (TEM) micrographs, the untreated group II evidenced a breakdown of the cuticle, severe necrosis in the epidermis and circular muscles, and a compromised intercellular matrix. Conversely, group III, treated with chitosan, showcased fibroblast growth, minimal changes in skin structure, and the development of new blood capillaries, indicative of granulation tissue formation (**Desmoulière *et al.*, 2005; Moisenovich *et al.*, 2016**). Contrastingly, the group treated with vasillan (Group II) displayed evident damage in TEM micrographs, with the breakdown of the cuticle, total necrosis in the epidermis and circular muscles, and obliteration of circular muscles. The intercellular matrix showed signs of edema, looseness, and limited vessel expansion, accompanied by the formation of new capillaries and fibroblast proliferation. In alignment with prior studies of **Desmoulière *et al.* (2005)** and **Moisenovich *et al.* (2016)**, our study corroborates the comprehensive nature of wound healing, encompassing capillary reconstitution, fibroblast activity, collagen formation, granulation tissue development, and tissue regeneration. This synchronicity underscores the efficacy of chitosan in promoting a swift and holistic healing response, positioning it as a noteworthy player in the realm of wound care (**Cossarizza *et al.*, 1996**).

Earthworms exhibit a distinctive capacity to assimilate dissolved chemicals from the soil through their body walls, facilitated by interstitial water. Additionally, they ingest these chemicals orally and coelom leading them through the digestive system, as described by **Yadav (2015)**. This elucidates the observed behavior of earthworms subjected to chitosan-dressed wounds. Notably, their bodies penetrate the materials, and the skin cells within the body wall undergo proliferation, forming multiple layers of cells covered by an epithelium layer. Furthermore, the muscular architecture, initially lost, undergoes reconstruction (**Stein & Cooper, 1981**).

In the investigation conducted by **Abbas *et al.* (2018)**, the impact of ZnO NPs on earthworms was explored. Their scrutiny of the body wall revealed that exposure to ZnO NPs resulted in fibrosis, vacuolation, and mucous proliferation. This finding elucidates the existence of empty spaces observed in the muscle layer of the tested animals' body wall. Simultaneously, these spaces may be attributed to hydropic edema. Consistent with

the current study, a loss of architecture in the body wall of wounded earthworms was also observed. Notably, they concur with our findings as they noted degenerated skin in group II of untreated animals, further emphasizing abnormalities in the body wall.

CONCLUSION

Administered directly to the wound site, chitosan's impact became evident in the context of infections inflicted upon (*Lumbricus castaneus*) earthworms. Notably, by the fifth day, a remarkable culmination of the infection closure and re-epithelialization process unfolded, exhibiting a noteworthy acceleration compared to conventional healing timelines. Furthermore, when chitosan was employed in the treatment, histological and transmission electron microscopy (TEM) investigations unveiled a distinctive scenario — an absence of inflammatory cells juxtaposed with an augmented presence of fibroblasts and capillaries. These findings underscore the prowess of chitosan in elevating the wound healing trajectory, presenting a landscape where inflammation is mitigated, and the regenerative elements thrive. While the study's outcomes paint a promising picture for chitosan's efficacy, the call for future investigations utilizing mammalian experimental models resonates, aiming to authenticate and expand upon these initial observations. The journey into understanding chitosan's impact on wound healing is an evolving narrative, inviting further exploration and validation in more complex biological contexts.

REFERENCES

- Abbas, M. ; Meeramaideen, M. and Mohamed, Sh.** (2018). Bioaccumulation and histological studies in ZnO nanoparticles exposed Eudrilus Eudenia. ERJLBPCS, 4(6): 388-397.
- Abd El-Aziz, F. A. ; Hetta, H. F.; Abd El-hamid , B.N. and Abd Ellah, N. H.** (2022). Antibacterial and wound-healing potential of PLGA/spidroin nanoparticles: a study on earthworms as a human skin model. Nanomedicine <https://doi.org/10.2217/nmm-2021-0325>.
- Abd El-Aziza, F.A. and Ali, M. F.** (2021). Towards Study of UV-C Radiation Effect on Earthworms and Isopods Via Electron Microscopy . Egypt. Acad. J. Biolog. Sci., 13(2): 33-46 Egyptian Academic Journal of Biological Sciences B. Zoology ISSN: 2090 – 0759 <http://ejbsz.journals.ekb.eg>.
- Abd El-Hack, M. E.; El-Saadony, M. T.; Shafi, M. E.; Zabermawi, N. M.; Arif, M. and Batiha, G. E.** (2020). Antimicrobial and antioxidant properties of chitosan and its derivatives and their applications: a review. Int. J. Biol. Macromol. 164: 2726–2744. doi: 10.1016/j.ijbiomac..08.153.

- Abd Ellah, N.H.; Abd El-Aziz, F. A.; Abouelmagd, S.A.; Abd El-Hamid, B.N. and Hetta, H.F.** (2019). Spidroin in carbopol-based gel promotes wound healing in earthworm's skin model. *Drug Dev Res.* 1–11. <https://doi.org/10.1002/ddr.21583>.
- Abdel-Rahman, R.M.; Hrdina, R.; Abdel-Mohsen, A.M.; Fouda, M.M.G.; Soliman, A.Y.; Mohamed, F.K.; Mohsin, K. and Pinto, T.D.** (2015). Chitin and chitosan from Brazilian Atlantic Coast: Isolation, characterization and antibacterial activity. *Int. J. Biol. Macromol.* 80:107–120. doi: 10.1016/j.ijbiomac.2015.06.027.
- Albro, P. W.; Bilski, P.; Corbett, J. T.; Schroeder, J. L. and Chignell, C. F.** (1997). Photochemical reactions and phototoxicity of sterols: Novel self-perpetuating mechanism for lipid photooxidation. *Photochemistry and Photobiology*, 66(3): 316–325.
- Bancroft, J. D. and Gamble, M.** (2008). *Theory and practice of histological techniques.* Elsevier Health Sciences.
- Cao, Y. ; Tan, Y.F. ; Wong, Y.S. ;Liew, M.W.J. and Venkatraman, S.** (2019) . Recent advances in chitosan-based carriers for gene delivery, *Mar. Drugs* 17 (6): 381.
- Chen, H.; Takahashi, S.; Imamura, M.; Okutani ,E.; Zhang, Z. and Chayama, K.** (2007). Earthworm fibrinolytic enzyme: anti-tumor activity on human hepatoma cells in vitro and in vivo. *Chin. Med. J.* 120: 898-904.
- Cooper, E.L.; Balamurugan, M.; Huang, C.Y.; Tsao, C.R.; Heredia, J. and Tommaseo-Ponzetta M.** (2012). Earthworms dilong: Ancient, inexpensive, noncontroversial models my help clarify approaches to integrated medicine emphasizing neuroimmuno systems. *Evid. Based Complement. Alternat. Med.* 164152. (doi:10.1155/2012/164152).
- Cooper, E.L.; Cossarizza A.; Kauschke E. and Franceschi, C.** (1999). Cell adhesion and the immune system: a case study using earthworms. *Micro. Res. Techn.* 44: 237-253.
- Cooper, E.L.; Hrženjak, T. and Grdiša, M.** (2004). Alternative source of fibrinolytic, anticoagulative, antimicrobial and anticancer molecules. *Int. J. Immunopath. Pharm.* 17: 237-244.
- Cossarizza, A.; Cooper, E.L.; Suzuki, M.M.; Salvioli, S.; Capri, M. and Gri, G.** (1996). Earthworm leukocytes that are not phagocytic and cross-react with several human epitopes can kill human tumor cell lines. *Exp. Cell Res.* 224: 174-182.

- Desmoulière, A. ;Chaponnier, C. and Gabbiani, G.** (2005). Tissue repair, contraction, and the myofibroblast. *Wound Repair and Regeneration*, 13 (1), 7–12.
- Drury, R.A. and Wallington, E.A.** (1980). *Carleton's Histological Techniques*. 5th Edition, Oxford University Press, New York, 195.
- Garg, U. ; Chauhan, S. ;Nagaich, U. and Jain, N.** (2019). Current advances in chitosan nanoparticles based drug delivery and targeting, *Adv. Pharm. Bull.* 9 (2): 195.
- Gomes, S. C.; Leonor, I. B.; Mano, J. F.; Reis, R. L. and Kaplan, D. L.** (2011). Antimicrobial functionalized genetically engineered spider silk. *Biomaterials*, 32(18): 4255–4266.
- Gupta, P. D.** (1983). Ultrastructural study on semithin section. *Journal of Sci Tools*, 30(1):6-7.
- Hoemann, C. and Fong, D.** (2017). Immunological responses to chitosan for biomedical applications, in: *Chitosan Based Biomaterials 1*, Elsevier, , pp. 45–79.
- Hosseinnejad, M. and Jafari S.M.** (2016). Evaluation of different factors affecting antimicrobial properties of chitosan. *Int. J. Biol. Macromol.* 85:467–475. doi: 10.1016/j.ijbiomac.2016.01.022.
- Islam, S.; Bhuiyan, M.A.R. and Islam, M.N.** (2017). Chitin and chitosan: Structure, properties and applications in biomedical engineering. *J. Polym. Environ.* 25:854–866. doi: 10.1007/s10924-016-0865-5.
- Kaur, S. and Dhillon, G.S.** (2015). Recent trends in biological extraction of chitin from marine shell wastes: A review. *Crit. Rev. Biotechnol.* 35:44–61. doi: 10.3109/07388551.2013.798256.
- Khan, M. A. and Mujahid, M.** (2019). A review on recent advances in chitosan based composite for hemostatic dressings. *Int. J. Biol. Macromol.* 124: 138–147.
- Kumari, P.; Chahar, M.; Veerapur, V.; Spandana, G.; Thippeswamy, B. and Badami, S.** (2013). Spider web ointment: A traditional based approach in cutaneous wound healing. *Indian Journal of Traditional Knowledge*, 12(4), 657–663.
- Li, M.; Liang, Y.; He, J.; Zhang, H. and Guo, B.** (2020). Two-Pronged strategy of biomechanically active and biochemically multifunctional hydrogel wound dressing to accelerate wound closure and wound healing. *Chem. Mater.* 32: 9937–9953. doi: 10.1021/acs.chemmater.0c02823.

- Misra, R.; Lal, K.; Farooq, M. and Hans, R.** (2005). Effect of solar UV radiation on earthworm (*Metaphire posthuma*). *Ecotoxicology and Environmental Safety*, 62(3): 391–396.
- Mohan, K., Ganesan, A. R., Muralisankar, T., Jayakumar, R., Sathishkumar, P. and Uthayakumar, V.** (2020). Recent insights into the extraction, characterization, and bioactivities of chitin and chitosan from insects. *Trends Food Sci. Technol.* 105: 17–42. doi: 10.1016/j.tifs.2020.08.016.
- Moisenovich, M.; Malyuchenko, N.; Arkhipova, A. Y.; Goncharenko, A.; Kotlyarova, M.; Davydova, L. and Debabov, V.** (2016). Recombinant 1F9 spidroin microgels for murine full-thickness wound repairing. *Doklady Biochemistry and Biophysics*, 466(1): 9–12.
- Pascoe, S. and Gatehouse, D.** (1986). The use of a simple haematoxylin and eosin staining procedure to demonstrate micronuclei within rodent bone marrow. *Mutat Res. Aug*; 164(4):237-43. doi: 10.1016/0165-1161(86)90057-9. PMID: 2427945.
- Philibert, T.; Lee, B.H. and Fabien N.** (2017). Current status and new perspectives on chitin and chitosan as functional biopolymers. *Appl. Biochem. Biotechnol.* 2017;181:1314–1337. doi: 10.1007/s12010-016-2286-2.
- Reynolds, J.W. and Reynolds, W.M.** (1972). Earthworms in medicine. *Am. J. Nursing* 72: 1273-1283.
- Salem, S. H.; El- Maraghy, S.; Abdel- Mallek, A.Y.; Mohamed A.A.; Abdel- Rahman; Emad H. M.; Hassanein, O. A. Al- Bedak and Abd El-Aziz, F. A.** (2022). The antimicrobial, antibiofilm, and wound healing properties of ethyl acetate crude extract of an endophytic fungus *Paecilomyces* sp. (AUMC 15510) in earthworm model *Scientific Reports* ,12:19239 <https://doi.org/10.1038/s41598-022-23831-4>.
- Samuel, J. R.; Elaiya Raja, S. C.; Beryl Vedha, S., Y.; Edith Arul Jane, A.; Amutha, K.; Dinesh, S. M. and Pitchumani, K.** (2011). Autofluorescence in BrdU-positive cells and augmentation of regeneration kinetics by riboflavin. *Stem Cells and Development*, 21(11): 2071–2083.
- Sara, M.; Ilyas, F.; Hasballah, K.; Nurjannah, N. ; Harapan, H. and Mudatsir, M.** (2023). *Lumbricus rubellus* earthworm as an antibacterial: A systematic review. *Journal of Applied Pharmaceutical Science* Vol. 13(12): pp 079-086. DOI: 10.7324/JAPS.2023.128228.
- Stein, E.A. and Cooper, E.L.** (1981). The role of opsonins in phagocytosis by coelomocytes of the earthworm *L. terrestris*. *Dev. Comp. Immunol.* 5: 415-425.

- Stevenson, J.** (1930). *Oligochaeta*, Claredon Press, Oxford.
- Verma, A. ; Tiwari, A.; Saraf, S.; Panda, P.K. ; Jain, A. and Jain, . S.K.** (2022). Protein and peptide delivery by chitosan systems, in: *Chitosan in Biomedical Applications*, Elsevier. pp. 211–228.
- Wangchuk, P.** (2018). Therapeutic applications of natural products in herbal medicines, biodiscovery programs, and biomedicine. *Journal of 10 ABD ELLAH ET AL. Biologically Active Products from Nature*, 8(1), 1–20. <https://doi.org/10.1080/22311866.2018.1426495>.
- Yadav, S.** (2015). Presence of Au-NPs in coelomic cells of earthworm *Eudichogaster prashadi* Stephenson. *Int.J.Curr.Microbiol.App.Sci.* 4(1): 1013-1021
- Yeul, V.S. and Rayalu S.S.** (2013). Unprecedented chitin and chitosan: A chemical overview. *J. Polym. Environ.* 21:606–614. doi: 10.1007/s10924-012-0458-x
- Zhou, L. ; Ramezani, H. ; Sun, M.; Xie, M. ; Nie, J. ; Lv, S. ;Cai, J. ;Fu, J. and He, Y.** (2020). 3D printing of high-strength chitosan hydrogel scaffolds without any organic solvents, *Biomaterials Science* 8 (18): 5020–5028.